

Frozen Shoulder: a Comparison of Western and Traditional Chinese Approaches and a Clinical Study of its Acupuncture Treatment

Emad S Tukmachi

Summary

A pilot study using acupuncture in the treatment of 31 patients with frozen shoulder showed marked improvement in 24 and improvement in 6. Patients with idiopathic or arthritic frozen shoulder responded better than those with post-traumatic aetiology. There was no relationship between response to acupuncture and age.

Although this study involved no control group, the high level of improvement together with the author's clinical experience suggests that acupuncture should be considered an effective option in the treatment of frozen shoulder; the more so since conventional medical therapy has a low expectation of benefit. Aetiology pathology and clinical management are described in both Western medical and traditional Chinese terms and details of acupuncture treatment methods are given.

Key words

Acupuncture, Age response, Capsulitis, Clinical study, Frozen shoulder, Periarthritis, Traditional Chinese medicine.

Introduction

Frozen shoulder is the result of a degenerative and inflammatory process affecting the articular capsule and the soft tissues of the shoulder (1). It has had a number of medical synonyms: scapulo-humeral periarthritis (2,3), adhesive capsulitis (4-6), pericapsulitis, and obliterative bursitis. In traditional Chinese medicine it is termed "Shoulder at the age of 50" (Table 1).

Frozen shoulder can be mild and self-limiting in its course, or it may become chronic and give rise to progressive degenerative changes. Generally, it is characterised by stiffness with limitation of movement, and pain which may be acute, subacute or chronic. In mild cases, pain and stiffness may settle within a short period of time, with or without treatment, but the management of subacute and chronic cases is often unsatisfactory with drug therapy. Other physical treatments such as heat, massage and manipulation may be equally

Table 1

SOME FACTS ABOUT FROZEN SHOULDER

1. The incidence of frozen shoulder in women is greater than in men, and occurs more often over the age of 50. The clinical features are of pain with a significant reduction of both passive and active movements (5), and pronounced sleep disturbance.
2. Frozen shoulder is more common in the non-dominant arm (7).
3. Although the exact pathology is unknown, the onset of frozen shoulder is usually gradual, but it may be acute and associated with previous history of minor injury to the shoulder joint (8).
4. In most cases frozen shoulder is unilateral, but it can be bilateral (9).
5. Frozen shoulder can induce secondary spasm in the pectoralis and biceps muscles (10).

unsatisfactory. In my own experience, acupuncture therapy for frozen shoulder has had the highest patient acceptance in preference to other methods of treatment.

The following approaches the subject from both Western and traditional Chinese medical points of view, examining the pathology, clinical features and management through both systems.

Western medical view

Aetiology

Although frozen shoulder remains one of those mysterious conditions with no definitive cause, there are some predisposing factors in its aetiology (Table 2) and a number of other problems appear to contribute to the condition:

- Trauma:* Injury resulting from a fall or other impact, strenuous exercise, lifting something too heavy, traction or over-torsion may lead to inflammation of the shoulder joint or capsule followed by restriction of glenohumeral joint movement (11).
- Cervical disc degeneration:* Cervical spine pathology at the level of C4-7 or T1 may be involved (10).

- iii. *Physical strain*: Excessive strain on the glenohumeral joint predisposes to inflammation and stiffness.
- iv. *Mental and psychological*: Factors such as tension, stress, anxiety and depression may have a psychosomatic effect (8,12).
- v. *Others*: Infection, repeated minor injury, rheumatic activity in and around the shoulder joint and auto-immune disease may all lead to frozen shoulder.

Table 2**PREDISPOSING FACTORS FOR FROZEN SHOULDER**

1. Immobility of the arm for a long period of time leading to muscle imbalance, as occurs in post myocardial infarction, diabetes, hemiplegia and in some chronic mental illnesses
2. Tendinitis of the rotator cuff
3. Biceps tendinitis and tenosynovitis of its long head
4. Congenital deformity in the shoulder girdle
5. Scapulo-costal cementing (fixation)
6. Ligamentous injury
7. Osteoarthritis
8. Sub-scapular muscular fibrositis
9. Nutritional deficiencies
10. Other diseases such as: diabetes mellitus, thyroid disease, reflex sympathetic dystrophy syndrome, coronary artery, scleroderma and avascular necrosis of the humeral head.

History and clinical features

Frozen shoulder tends to affect patients above the age of 50. It is known to accompany Sudeck's atrophy: shoulder joint stiffness and patchy osteoporosis. Occasionally, frozen shoulder is seen in patients with Shoulder-Hand Syndrome (adhesive capsulitis) which is characterised by hand swelling with osteoporosis. Frozen shoulder pathology has three phases (13,59) which may take up to 2 years to resolve or even longer.

- i. *Freezing phase (3-9 months)*: The patient is usually healthy, but with a history of minor shoulder injury, and presents with a gradual onset of shoulder pain and stiffness. Although active movements are painful and restricted, the adhesions have not yet formed.
- ii. *Frozen phase*: The patient is pain-free but stiff, experiencing muscle wasting due to lack of movement at the gleno-humoral joint (*i.e.* disuse atrophy). Adhesions are present in the joint capsule.
- iii. *Thawing phase*: During this phase the shoulder movement gradually returns.

Subjective clinical examination: This relates to the patient's account of the complaint and to the previous history. The skill in getting the appropriate information from the patient requires care, patience and a critical attitude. The aim of this examination is to ascertain the area of pain and its depth, and the nature and behaviour of the pain in relation to various activities, determining how easily the patient's symptoms are aggravated by those activities and how readily the symptoms subside, so that exacerbation from excessive physical examination can be avoided.

Objective clinical examination: This interprets the patient's concept of the disability, assessing both active and passive movements to determine the functional limits imposed by the frozen shoulder. The active movements should be tested first because patients will perform these within their own limits of pain, and therefore without distress; the assessment of these movements will indicate the severity and the disability, and guide the clinician as to how much passive handling the joint will tolerate. There are some distinct signs and symptoms found in this condition:

- i. The main complaint is of intense pain, particularly when attempting to move the arm into or near the restricted range of movement. The pain is felt on the outer part of the upper arm and it is dull in nature but sharp with movement. Usually the patient is unable to sleep on the affected shoulder joint.
- ii. The range of motion is restricted (to about 50% of normal): mainly external rotation, abduction and flexion. It is usually difficult for the patient using the affected shoulder to reach behind the head and touch the upper medial angle of the opposite scapula, reach in front of the head and touch the opposite acromion, throw a softball overarm a distance of 20 yards, place a coin on a shelf at the level of the shoulder without bending the elbow, lift 5 kilos to the level of the top of the head while bending the elbow, and wash the back of the opposite elbow.
- iii. The patient may have restricted scapular movement.
- iv. There may be signs of fibrositis in the surrounding musculature, particularly in the trapezius, deltoid, teres minor and major, infraspinatus, and subscapularis muscles.
- v. A diffuse tenderness may be elicited in the rotator cuff muscles, more marked anteriorly, due to guarding at the shoulder joint. The diagnosis of this condition depends on the history, clinical features and clinical examination

Table 3**DIAGNOSTIC POINTERS FOR FROZEN SHOULDER****History**

Previous history of shoulder injury or surgery in patients between 50 and 60 years old

Clinical features

Dull, aching or stabbing pain on the outer part of the upper arm, sharp with movement of the shoulder joint
A restricted range of movement (both active and passive)
Tenderness in the rotator cuff

Clinical examination

Limitation of all glenohumeral active and passive movements

Investigations

X-ray (plain and arthrography), MRI and thermography are used to exclude any previous fracture or dislocation and will show either no changes or some degenerative change.

(Table 3), and may be confirmed by X-ray investigation of the shoulder joint (9,14). Arthrography may show no changes in the first phase, but in the second phase certain signs can be seen, such as a reduction in the volume of the glenohumeral joint cavity and some changes in the scapulo-humeral angle at 30° of abduction. There is also marked contracture of the joint capsule with obliteration of the axillary fold, and lack of dye filling the bicipital sheath.

Magnetic resonance imaging (MRI) may be helpful in the diagnosis of degenerative changes in the shoulder and to determine capsular thickening: a joint capsule and synovium thickness in excess of 4mm is diagnostic of frozen shoulder (1.5). Thermography is another diagnostic tool: Vecchio (16) found that the skin temperature in frozen shoulder may be lowered as a result of sympathetic dysfunction.

Frozen shoulder should be differentiated from other conditions with pain and stiffness affecting the shoulder joint, such as tendinitis and bursitis, rotator cuff tears, posterior dislocation, acromio-clavicular osteoarthritis, avascular necrosis of the humeral head, gouty arthritis of the glenohumeral joint, rheumatoid arthritis, polymyalgia rheumatica and neoplastic disease (Pancoast's tumour).

Management

In the management of frozen shoulder (25), the clinician needs the skills of diagnostician, healer and counsellor. His tasks include the identification of the complaint and the elucidation of its causes, and he may need to provide advice, support and analysis. The doctor-patient relationship, then, is central to the treatment.

General measures in the management of frozen shoulder depend on diagnosis at the earliest possible stage, as this may prevent onset of the pathological phases. A traumatised shoulder in the vulnerable 50-60 age group should be re-examined for up to two months after the injury to detect inflammation in the shoulder joint which may lead to capsulitis. During the pathological phases many patients may develop a peri-arthritis personality, characterised by anxiety and depression (10); therefore reassurance and medical treatment of secondary depression and anxiety are essential. Additionally, it is important to diagnose and correct nutritional deficiencies produced by poor diet.

The initial treatment is aimed at reducing inflammation and increasing the range of movement, thus analgesic and anti-inflammatory drugs (29) are commonly used in the treatment of frozen shoulder; dosage is similar to that used in osteoarthritis. *Aspirin* may provide temporary control of pain, but has the possible side effect of gastric irritation, ulceration and bleeding. *Paracetamol* is regarded as safe for mild to moderate pain as, unlike *aspirin*, it does not irritate the stomach, but it is a less potent anti-inflammatory drug. The non-steroidal anti-inflammatory drugs (NSAIDs) have the same mode of action as *aspirin*, but their side effects are more prominent: epigastric discomfort, nausea, gastritis, gastric ulcer and haemorrhage, skin rash, blood disorders, renal failure, and others. Commonly used NSAIDs include: *ibuprofen*, which has the lowest incidence of side effects, *naproxen* and *diclofenac*.

Local injection of cortisone (7 1,77,18) has been advocated as a popular treatment; however, although some patients respond temporarily to infiltration of tender spots with cortisone, often combined with local anaesthetic, there is a small risk of tendon rupture (26,27) following exercise (28).

Surgery (19,20,30,31) is indicated for patients who have not improved after more than 4 months of physical therapies. However, it is contraindicated in patients with significant depression, autonomic dystrophy, debilitation or poor health. Arthroscopic release is usually more beneficial than open surgery because there is less dissection and less scarring. In recent years, it has been claimed that arthroscopic treatment of frozen shoulder improves mobility, function and pain much better than conservative therapy. It is contraindicated in patients with contracture due to an extra-articular aetiology, those sensitive to fluid challenges and possibly those with post-traumatic stiffness (32).

Physical treatment (20,24) includes physiotherapy, massage, heat application, ultrasound,

interferential, osteopathic and chiropractic techniques, and stretching and isometric exercise therapy. Manipulation under general anaesthesia (22,23,33,34) is helpful in non-progressive conditions or in patients with a low pain threshold. However, there is risk of humeral fracture or rotator cuff tear with excessive torque in external rotation, and it is contraindicated in those with epilepsy because of the risk of rapidly increasing both the inflammatory reaction and fibrous adhesions; also special care is needed with diabetics (33). The Western medical management of frozen shoulder is summarised in *Table 4* (see also Figure 6).

Table 4

WESTERN MEDICAL MANAGEMENT OF FROZEN SHOULDER

Early diagnosis and prevention

Investigation of shoulder injury in patients aged between 50 and 60

Investigation and treatment of patients with persistent (>6 weeks) shoulder pain and stiffness

Management of anxiety, physical and mental stress, fatigue and depression (10)

Correction of nutritional deficiency

Drug therapy

Steroid (local injection) (11,17,18)

Analgesic and non-steroidal anti-inflammatory drugs

Surgery

Arthroscopic or open capsular release (19-21)

Physical Treatment

Manipulation under anaesthesia (22,23)

Physiotherapy and other physical therapies (20,24)

Traditional Chinese medical view

Aetiology and pathology

According to traditional Chinese medicine (TCM), frozen shoulder belongs to the blockage group of diseases or to Bi syndrome (painful locomotor disorders). The definition of Bi in Chinese medicine is obstruction or interference with the flow of *qi* (vital energy) and Blood. It is usually caused by an invasion of Wind, Cold and Dampness in the intermediate network of channels and collaterals, disrupting related muscle function (44). The blockage results in pain, aching and stiffness in the muscle, bones, tendons and joints. There are four main types of Bi syndrome:

i. *Wandering Bi*: in which Wind predominates, as it is either exterior or interior. The exterior Wind has usually invaded the body from the outside, while the interior may result from *qi* deficiency or deficiency of Blood. The syndrome is characterised by a flitting pain in the joints of the

extremities, with stiffness. The cause is mainly due to the attack of external Wind. There may be a thin, white, sticky coated tongue, and a superficial, floating and rapid pulse. The patient with wandering Bi syndrome usually reacts negatively to windy weather.

- ii. *Painful Bi*: in which Cold predominates, since the arthralgia responds to warmth and is aggravated by cold, especially in winter in the absence of inflammation. The Cold may be external or internal. It is characterised by a severe, stabbing, joint pain associated with stiffness. There may be a thin, white coated tongue, and a tight and deep wiry pulse.
- iii. *Fixed Bi*: in which Damp predominates. It is characterised by joint stiffness and mild, fixed pain associated with numbness in the surrounding tissues. The syndrome is usually provoked by cloudy and/or wet weather. The patient may have a yellow coated tongue and a rolling, rapid pulse.
- iv. *Febrile Bi*: in which Heat predominates and Wind, Cold and Damp turn into heat. The arthralgia in this syndrome is characterised by chronic severe pain, local redness, tenderness and swelling. Fever and thirst are also main symptoms. One or more joints may be involved, with the cardinal signs of inflammation: heat, redness and swelling. The patient may have a dry, yellow coated tongue and rolling, rapid pulse.

Acupuncture

In 1871 Teale (35) stated that his friend wrote to him "I remember at the Birmingham hospital it was all the fashion at one time. We used to stick half-a-dozen needles into the deltoid and leave them for a quarter of an hour, with sometimes wonderful results." (36).

According to TCM, the acupuncture treatment of frozen shoulder is to disperse the excess Wind, Cold and Dampness and to remove the obstruction in the affected meridians and their collaterals, spreading the *qi* and Blood (37). The acupuncture prescriptions are designed, through the selection of local, distal and tender (*ashi*) points according to the course of the meridians, to relax the muscles, remove the obstruction, regulate *qi* and Blood and remove the pathogenic factors (38).

Traditional Chinese doctors regarded acupuncture as an effective measure in aborting the signs and symptoms of frozen shoulder and also in preventing future recurrence. However, acupuncture treatment is a time-consuming procedure, as each session of treatment may last for about 30 minutes and in many patients 5 to 15 sessions or more may be needed.

Acupuncture method

In the treatment of frozen shoulder, as in many other diseases, 1 in long, 30 gauge, disposable, sterilised, filiform needles are usually used. The therapeutic effect was found to be at its best when the patient had a feeling of needle sensation (*deqi*), such as tingling, numbness, soreness, dull pain, heaviness or distention, at the site of the needle insertion. Propagation of one or more of these sensations may occasionally be felt along the channel. The sensation of *deqi* must be distinguished from pain or discomfort due to needling technique. In each session the needles are retained for 20 to 30 minutes. Patients should be warned that symptoms may worsen temporarily before benefit is noted.

Two strengths of stimulation may be used in normal medical practice. Strong stimulation may be achieved by needle rotation simultaneous with lifting and thrusting movements. The needle is twirled at up to 200 rotations per minute with an arc of 120-180°. This method of either reducing or reinforcing is continued until the acupuncture sensation (*deqi*, is felt, and is repeated if necessary. It is usually prescribed for robust patients suffering from acute onset of frozen shoulder. For Mild stimulation the needle is rotated 60-90° immediately after the occurrence of the desired needling sensation. This mild reducing and reinforcing technique is applied to patients with a weak constitution, suffering from chronic frozen shoulder.

Generally, after 4 sessions of treatment, with each session lasting up to 30 minutes, a good result is obtainable. However the outcome should be considered ineffective when there is no change in a patient's signs and symptoms after 6 sessions of treatment.

Point selection

Trigger points

Trigger points, also called tender or *ashi* points, are located in the muscles of the affected shoulder joint, particularly the deltoid, pectoralis, biceps and trapezius, and they need to be searched for in a careful and systematic manner. Deactivation of these trigger points can be performed by superficial manual stimulation with a needle depth of 3 to 5mm (39,40). The main trigger points to be found in frozen shoulder are illustrated in Figure 1.

Traditional acupuncture points

A combination of local and distal (37,41) classical Chinese body acupuncture points (Table 5 and Figure 2) are commonly used. In the first session, the needling of ST.38 with fairly strong stimulation is

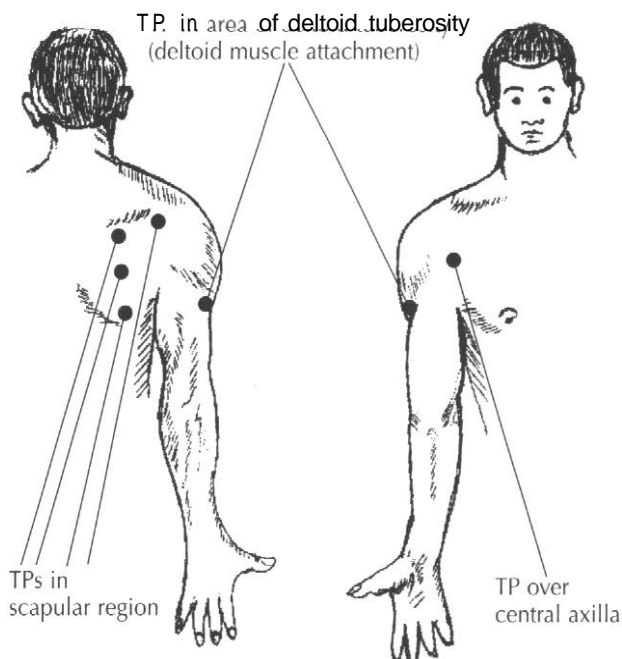


Figure 1. Trigger points (TP) used in the treatment of frozen shoulder.

useful in mobilising the shoulder. It has been reported that in 70-80% of cases significant improvement is obtained immediately (42). In another study, Nguyen (43) found that 10 minutes of deep needling at ST.38 eased shoulder stiffness.

Electroacupuncture has been used in some cases with a better response than manual acupuncture. The best combination of acupuncture points is reported to be: LI.1 and LI.15, GB.21 and SI.9 using a frequency of 5Hz for a period of 10-20 minutes (45).

Usually a minimum of four points is used at each treatment session, but from my experience I have found that for many frozen shoulder sufferers bilateral needling of CB.34 (*Yanglingquan*) alone for about 2 minutes is sufficient to control the pain and release the stiffness (Figure 3).

It has been reported by Felix Mann that periosteal acupuncture of the tip of the coracoid process and/or cervical articular pillar may help in the treatment of frozen shoulder (46). However, periosteal acupuncture is contraindicated in the presence of acute inflammation and in patients with a low pain threshold.

Ear acupuncture points

The key to success in auriculotherapy depends on the accurate detection of tender points on the ear, using a test probe. According to traditional Chinese medicine (47), the sensitive spots on the auricle are

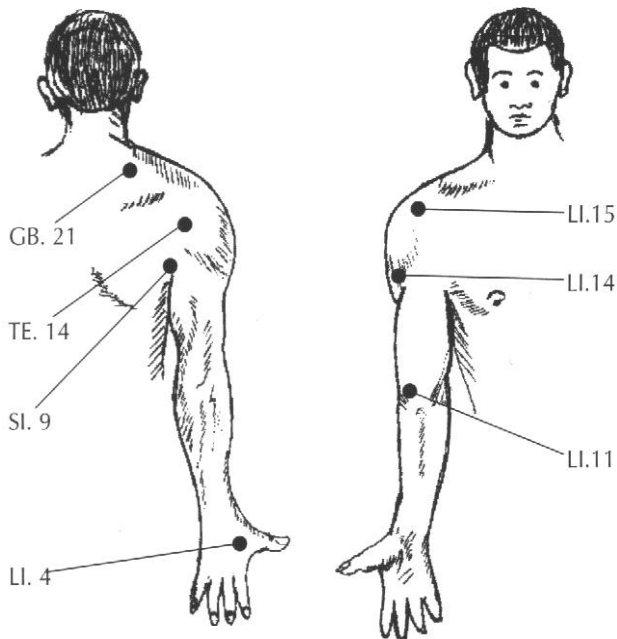


Figure 2. Some acupuncture points used in the treatment of frozen shoulder.

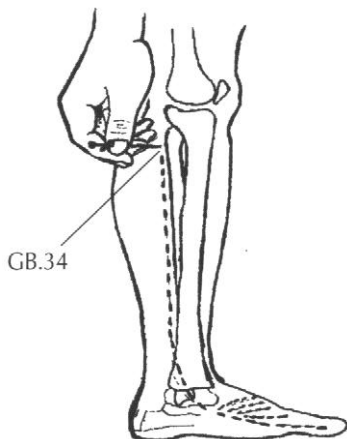


Figure 3. Needling of GB.34 showing propagation of needle sensation down the leg (.....) to one or more toes from the site of needle insertion.

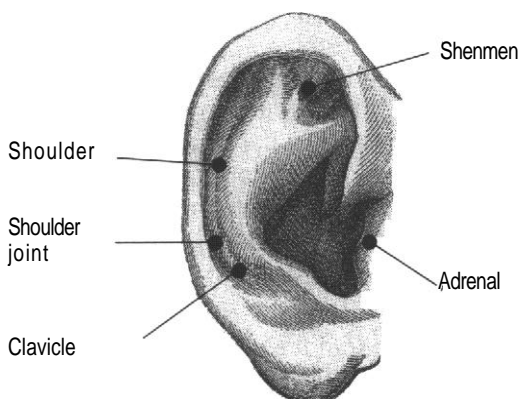


Figure 4. Ear acupuncture points in the treatment of frozen shoulder.

Table 5

TRADITIONAL ACUPUNCTURE POINTS USED FOR FROZEN SHOULDER

Local Points

Gall bladder 21 (Jianjing) is located at the highest point of the shoulder, midway between GV.14 (*Dazhui*) and LI.15 (*Jianyu*).

Large intestine 15 (Jianyu) is located, with the arm abducted, in the anterior depression on the lateral border of the acromion process.

Large intestine 14 (Binao) is located on the lower border of the deltoid muscle on the line between LI.11 (*Quchi*) and LI.15 (*Jianyu*).

Triple energizer 14 (Jianliao) is located, with the arm abducted to a horizontal position, in the posterior depression of the origin of the deltoid muscle from the lateral border of the acromion.

Small intestine 9 (Jianzhen) is located one cun superior to the highest point of the posterior axillary fold.

Distal points

Large intestine 4 (Hegu) is located in the web between the abducted forefinger and the thumb at the highest point of the muscles of the back of the hand.

Large intestine 11 (Quchi) is located at the lateral end of the elbow crease when the elbow is semiflexed.

Stomach 38 (Tiaokou) is located 5 cun distal to ST.36 (*Zusanli*), or one finger's breadth lateral to the anterior border of the tibia.

Gall Bladder 34 (Yanglingquan) is located in the depression anterior and inferior to the small head of the fibula.

anatomically and pathologically related to the affected shoulder joint. In frozen shoulder, the following anatomically related ear acupuncture points (figure 4) are usually used for diagnosis and treatment: *shoulder point*: at the scapha on the same level as the suprtragic notch; *shoulder joint point*; at the scapha, lying between *shoulder* and *clavicle* points; and *clavicle point*: at the scapha on the same level as the neck *point* and the junction of the antihelix and antitragus.

Additionally, specific ear points are commonly selected for the treatment of specific symptoms. *Shenmen point*, at the bifurcation of the crura of the antihelix, has a broad-spectrum of action. The stimulation of this point has good sedative, analgesic and anti-inflammatory effects. *Adrenal gland point*, at the lower projection of the tragus, represents the adrenal gland with the function of regulating the cortical hormones. It is used in treating inflammation and rheumatological symptoms.

Insertion of needles may be perpendicular or oblique, but some important precautions must be considered to reduce the risk of infection. The ear should be cleaned before needling, and needles should not penetrate the cartilage or be manipulated by hand while in the ear. If manipulation is required, electro-stimulation may be used. In my opinion, the results obtained with combined ear and body acupuncture are generally better than with body acupuncture alone.

Shoulder exercises

In the view of Western physiology, when there is little or no movement of a joint the synovial fluid becomes relatively viscous. Thus, when an attempt is then made to increase the range of movement, the joint feels stiff and is difficult to move. A gradual warm-up at the start of exercise will reduce the viscosity of the synovial fluid, thereby making the joint easier to move and enhancing performance.

According to TCM, if a part of the body is not moved, then the vital energy (qi) will not circulate through it, leading to stagnation. If this occurs in the shoulder joint it becomes stiff and painful. Physical exercise is important in harmonising the body (yin) and the spirit (yang) as well as the vital energy, which in turn is essential for internal harmony between various organ systems as well as between the body and the natural environment (48).

There are particular exercises designed to accompany acupuncture treatment of frozen shoulder. These are maximally effective when applied in the early stages, as they aid in the reduction of pain and promote healing so that chances of an acute frozen shoulder progressing to a chronic one are minimised. However, almost any exercise can be harmful if done incorrectly or excessively. The level of fitness and basic working

order of the untrained patient must therefore be borne in mind, and careful instruction should be given to the patient when demonstrating the exercises (Figure 5).

- i. *Towel exercise*: The patient should hold a towel behind the back with the normal arm above, pulling up towards the ceiling. Then holding the towel with the normal arm below, the patient should pull down towards the floor. This type of exercise should begin after the first acupuncture session starting with 10 times each morning, midday and evening increasing gradually to a maximum of 20.
- ii. *Lifting exercise*: A cup is placed on a low shelf, lifted up to a shelf above head level and then down again. This exercise should be repeated 5-10 times, three times a day, but not until the shoulder pain has settled. The aim is to release the stiffness.
- iii. *Swinging exercise*: The patient should support the normal arm on a table or chair while the frozen arm hangs down and swings freely to front and back 30 times in pendulum fashion. This rhythmical mechanical mobilisation is very useful when treating frozen shoulder and should be performed frequently during the day.

Prognosis

Spontaneous recovery of frozen shoulder may take place within two years of onset without any form of treatment. However, many do not improve without appropriate treatment. In 1992, Shaffer et al (49) reported a long-term follow-up of idiopathic frozen shoulder. The authors evaluated subjectively and objectively 62 patients who had been treated non-operatively, at two years and two months to eleven years and nine months follow-up. They found that 50% of their patients still complained of either mild

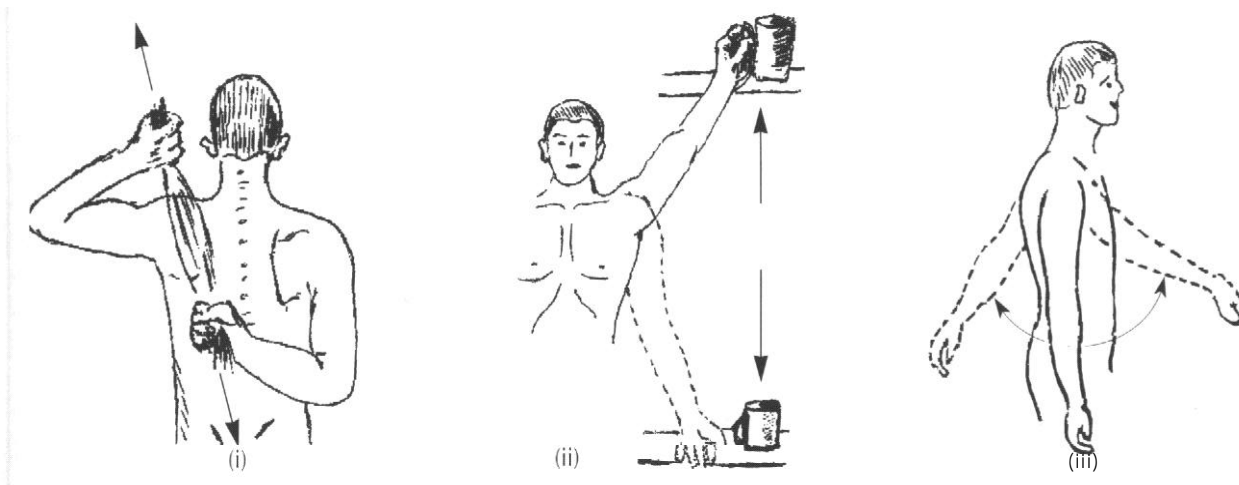


Figure 5. Shoulder exercises: (i) Towel exercise, (ii) Lifting exercise, (iii) Swinging exercise.

pain or stiffness of the shoulder or both, while 60% still showed some restriction of movement compared with study-generated control values.

Using acupuncture the prognosis is excellent. Acupuncture has been described as a useful treatment of shoulder pain (50-52) and I have found in my clinical study of frozen shoulder detailed below that between 80% and 100% of shoulder mobility is eventually restored with a recovery time varying from 2-14 weeks, depending on the chronicity of the condition (Figure 6).

In general, the prognosis of frozen shoulder when treated with acupuncture depends on the following factors:

i. Duration of acupuncture treatment: Usually within the first few treatment sessions the patient notices a favourable change in the quality, if not the quantity, of pain.

ii. Method of needle stimulation: This should be designed to suit the individual case. The stronger the stimulus up to a point, the better the relief of symptoms. However, over stimulation may have some adverse effects. The intensity of manual needle stimulation increases with depth of needle insertion, thickness of the needle, amplitude and frequency of rotation, the time the needle is left in situ after stimulation, and the number of points used for treatment.

iii. Previous steroid therapy: When a frozen shoulder has been treated with steroids over a long period, recovery with acupuncture usually takes longer.

iv. The acupuncture points: Inaccuracy in the location and selection of points may lead to indifferent results.

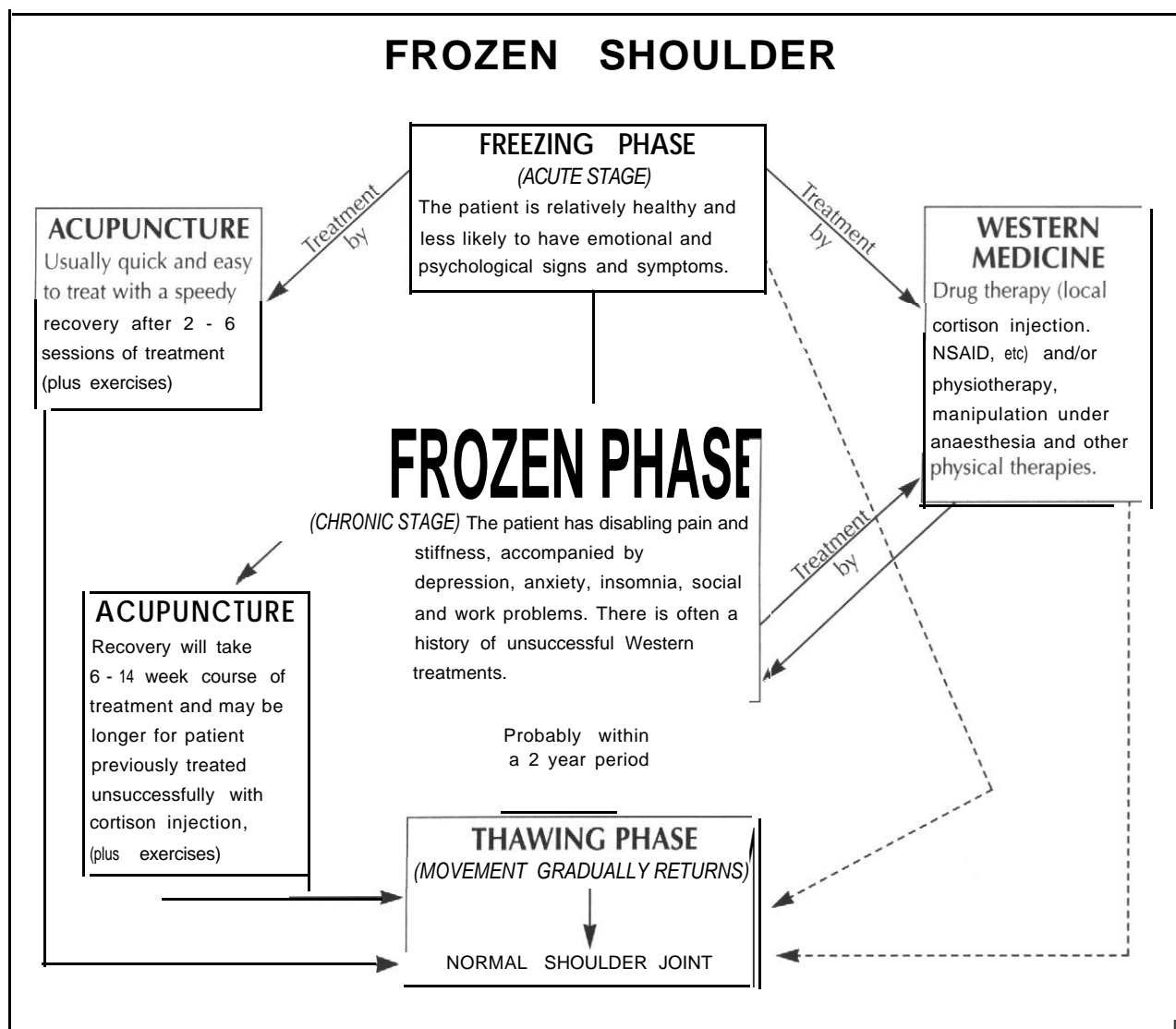


Figure 6. Scheme of management and prognosis of frozen shoulder.

A pilot clinical study of 31 frozen shoulders

Introduction

Acupuncture has been used as a prophylactic and therapeutic medical tool in China for more than 5000 years (53,54), and is now proving valuable in modern medical practice as an effective therapy for musculo-skeletal problems, including frozen shoulder, particularly where current Western medicine is either ineffective or contraindicated (39,50-52,55-58).

Frozen shoulder is a common, but not well understood, disorder affecting the gleno-humeral joint, possibly involving loss of resilience of the joint capsule and the development of adhesions between the synovial folds. The main clinical features of the typical frozen shoulder are severe aching in shoulder and upper arm sometimes with tenderness around the area, often preventing sleep because of difficulty in finding a comfortable position in bed. The onset of frozen shoulder may be gradual or rapid, with all glenohumeral movements becoming restricted to about 25% of normal. Information on aetiology, treatment and prognosis of frozen shoulder is inadequate and based largely on individual practice experience rather than controlled clinical trials.

Ekelund and Rydell (59) have reported treating 23 frozen shoulders using a combination of distention-arthrography with local anaesthetic and intra-articular injection of steroid. They found that 91% of patients (21 out of 23) improved with the combination treatment after a period of 4-6 weeks, with 83% of patients (19 out of 23) returning almost to a normal range of mobility. Despite these findings, however, patients with frozen shoulder commonly get little relief from conventional medical treatment or physiotherapy.

Method

Over four years I have treated 31 patients suffering with frozen shoulder (18 male, 13 female); the youngest was 36 and the oldest 93 (Table 6). Frozen shoulder had been diagnosed by the general practitioner or specialist as idiopathic, arthritic or post-traumatic.

The data for duration prior to acupuncture treatment, the number of acupuncture sessions and the response to acupuncture for these three types of frozen shoulder are presented in Table 7, with the exception of the one case classed as a failure.

All patients presented had had one or more of the

Table 6
DEMOGRAPHIC DATA FOR PATIENTS IN FROZEN SHOULDER STUDY

Patient	Age	Sex	Cause	Duration	Sessions	Response
1	57	M	Idiopathic	1.5	13	improved
2	36	M	Post-trauma	3	5	improved
3	46	F	Idiopathic	6	8	marked
4	59	M	Idiopathic	6	5	marked
5	51	M	Post-trauma	4	10	marked
6	60	F	Arthritic	9	10	marked
7	39	F	Idiopathic	1	3	improved
8	65	F	Arthritic	3	8	improved
9	37	M	Post-trauma	36	4	improved
10	60	F	Post-trauma	24	15	marked
11	59	M	Arthritic	36	14	marked
12	57	F	Idiopathic	9	11	marked
13	63	M	Idiopathic	2	2	failed
14	64	M	Idiopathic	6	8	marked
15	80	F	Arthritic	2	6	marked
16	50	M	Post-trauma	24	15	marked
17	81	M	Arthritic	24	12	marked
18	62	F	Idiopathic	24	6	marked
19	66	F	Arthritic	2	6	marked
20	78	M	Arthritic	10	10	marked
21	67	F	Arthritic	6	4	marked
22	45	F	Arthritic	36	9	marked
23	62	M	Arthritic	24	10	marked
24	62	M	Arthritic	4	12	marked
25	53	M	Idiopathic	1	5	marked
26	77	M	Arthritic	4	6	improved
27	69	M	Arthritic	6	6	marked
28	57	M	Idiopathic	36	6	marked
29	46	M	Idiopathic	15	10	marked
30	62	F	Post-trauma	24	6	marked
31	93	F	Arthritic	36	12	improved

Duration is in months before start of treatment.

Patients grouped according to year treatment was started (1994 to 8).

following conventional treatments without therapeutic effect: anti-inflammatory or analgesic medication, physiotherapy, steroid injection, chiropractic or osteopathic manipulation. None had had surgery to the shoulder. The methods of acupuncture treatment (including ear acupuncture) in this study have been described above.

Clinical assessment of each patient was carried out at the beginning and end of each course of acupuncture treatment and objective functional changes were recorded. Long term follow-up (two years post-treatment) was not undertaken because it is very rare for this disorder to recur, nor was the

Table 7
FROZEN SHOULDER RESPONSE TO ACUPUNCTURE ACCORDING TO AETIOLOGY

Cause	Total cases n=30	Duration before treatment		Number of sessions		Response	
		1-24 months	25-48 months	4-8	9-16	Markedly improved	Improved
Idiopathic	10 (33%)	9 (30%)	1 (3%)	7 (23%)	3 (10%)	8 (27%)	2 (7%)
Arthritis	14 (47%)	11 (37%)	3 (10%)	6 (20%)	8 (27%)	11 (37%)	3 (10%)
Post-traumatic	6 (20%)	5 (17%)	1 (3%)	3 (10%)	3 (10%)	4 (13%)	2 (7%)

Table 8
RELATIONSHIP BETWEEN AETIOLOGY OF FROZEN SHOULDER AND ACUPUNCTURE TREATMENT RESPONSE

Response	Idiopathic	Arthritic	Post-traumatic
Improvement	2	3	2
Marked improvement	8	11	4
	p=0.05	p=0.03	p<0.5

Table 9
RELATIONSHIP BETWEEN DURATION OF FROZEN SHOULDER AND ACUPUNCTURE TREATMENT RESPONSE

Response (n=30)	Duration of frozen shoulder	
	1 to 6 months	9 to 36 months
Improvement	5	2
Marked improvement	10	13
	p<0.5	

response with one exception: failure was recorded for one patient who withdrew from treatment after only 2 acupuncture sessions (*Table 6*). Of the remaining 30 cases in this pilot study, 23 (77%) had marked improvement and 7 (23%) improved (*Table 7*).

Table 8 compares the response to acupuncture for each of the three causes of frozen shoulder being studied. Using the Chi-squared test a significant difference is found between the markedly improved and improved response for both idiopathic (p=0.05) and arthritic (p=0.03) types of frozen shoulder, but not for post-traumatic (p<0.5).

Similarly, *Table 9* compares response with short or long duration of the frozen shoulder before start of acupuncture treatment. Again, the Chi-squared test demonstrates a significant difference (p=0.02) between the response for short and long duration of disease, suggesting that acupuncture treatment is more effective in later stages of the disease, although this could well be a reflection of natural recovery.

When comparing the number of sessions necessary for maximum benefit from the acupuncture treatment of frozen shoulder (*Table 10*)

Table 10
NUMBER OF ACUPUNCTURE SESSIONS NECESSARY FOR MAXIMUM BENEFIT

Response (n=30)	Number of acupuncture sessions	
	4 to 8	9 to 15
Improvement	5	2
Marked improvement	11	12
	p=0.1	

Table 11
RELATIONSHIP BETWEEN RESPONSE TO ACUPUNCTURE AND AGE OF PATIENT

Response (n=30)	Age (years)	
	36 to 59	60 to 93
Improvement	3	2
Marked improvement	11	14
	p<0.5	

effect of acupuncture on the pathological process of frozen shoulder investigated. Post-therapeutic evaluation was based on the following criteria:

- Failed*: No apparent response was reported to a least four sessions of treatment.
- Improved*: A significant reduction in shoulder pain was noted. Activity and mobility in the affected shoulder had improved and requirement for Western medication had been reduced or stopped.
- Marked improvement*: All signs and symptoms of frozen shoulder had disappeared or had decreased by over 80% compared with the state before treatment. Activity and well-being had significantly improved so that patients had been able to return to normal mobility.

Results

The 31 patients were assessed for the causes of frozen shoulder, pre-treatment duration of the disease, the number of acupuncture sessions, and the clinical response. All patients had a beneficial

no significant difference ($p=0.5$) was found in the degree of benefit between patients requiring a large or small number of treatments. Thus some patients can obtain therapeutic effect with only 4 sessions of treatment, while others may need up to 15 for the same level of benefit.

The patients were divided according to age into two groups: aged 60 and above, and below 60 (Table 11). There was no significant difference ($p<0.5$) in response to acupuncture between the two age groups.

Discussion

In this pilot study, analysis of the therapeutic effects of acupuncture on 30 cases of frozen shoulder showed a marked improvement in 24 (80%) and an improvement in 6 (20%). Considering the aetiology: when subdivided into the three causes studied, there was a significant difference between the markedly improved and improved responses for both idiopathic ($p=0.05$) and arthritic ($p=0.03$) groups, suggesting that both these forms of frozen shoulder can be expected to respond well. The difference in response was not significant for the post-traumatic frozen shoulder group; however the number of patients in this group was small ($n=6$), with consequently unreliable statistics.

The 30 patients were divided in two equal or nearly equal groups according to several demographic parameters to see if these influenced the response to acupuncture. A significant difference ($p=0.02$) in degree of benefit was found between patients with short or long duration of frozen shoulder prior to treatment. However, the greater benefit seen when treatment was started late in the disease cycle could well be due to a natural history of resolution with time.

Looking at the number of treatments necessary for a patient to obtain maximum benefit from the acupuncture showed a wide spread of from 4 to 15 sessions, with no significant difference between the degree of improvement obtained by those having many treatments and those having few. Thus it appears to be individual response rather than a specific optimum number of treatment sessions that determines both the amount of benefit and the speed of recovery in acupuncture treatment.

There was no significant difference between the level of benefit obtained by the older patients aged 60 and above, and those below 60. This would seem to belie the popular assumption that older patients respond less well to acupuncture, at least as far as frozen shoulder is concerned.

Although this type of uncontrolled clinical evaluation study has a limited value in assessing

therapeutic efficacy, it should provide additional data that will help to define the active role of acupuncture in treatment of frozen shoulder, particularly in those not responding well to the conventional therapy.

Case histories

Markedly improved response

A 46 year-old lady was referred by her GP for acupuncture treatment of her right frozen shoulder. She described her right shoulder as becoming increasingly stiff and painful over a period of 6 months. Initially her shoulder pain occurred with activity as well as at rest; it also caused difficulty in finding a comfortable position in bed. She reported reduced shoulder function: lifting to shoulder height, washing the back of her opposite shoulder, throwing overhand, and tucking in a shirt behind; this reduced range of shoulder movement significantly limited the activities of her daily living. She had no history of traumatic injury to the shoulder joint or any other illnesses. She had had no improvement of her symptoms with conservative medical treatment.

Physical examination of the right shoulder revealed a limited range of movement (to about 50% of the opposite side): in total elevation (combined glenohumeral and scapula-thoracic motion), external rotation with the arm at the side, external rotation in the 90° abduction position, internal rotation (ability to touch thoracic spine) and abduction. The diagnosis of frozen shoulder was made on the history, clinical features and physical examination.

My treatment consisted of inserting needles and using electro-acupuncture, and asking her to exercise the affected shoulder every day by the methods described earlier in this paper (*Shoulder exercises*). The acupuncture method and points used were those discussed earlier (*Acupuncture method and Point selection*). A minimum of six acupuncture points was usually needled on each occasion, plus some trigger points.

The patient's response to acupuncture was excellent following eight treatment sessions, with significant improvements in the severity of her pain and stiffness, giving increased shoulder mobility.

Improved response

A 77 year-old man had a history of painful and stiff right shoulder for four months. The patient said the symptoms had come on gradually with no previous history of pain or injury. His main symptoms were an aching pain in the shoulder at night and a reduced range of movement in the shoulder joint,

He described the pain as progressive over a period of weeks resulting in loss of joint mobility.

He reported difficulty with overhand throwing, sleeping comfortably on the affected side, washing the back of the opposite shoulder, and lifting to shoulder height. After a full clinical examination, he was told by his physician that he had a right osteoarthritic frozen shoulder, and he was then treated unsuccessfully with a variety of conventional medical therapies.

When I saw the patient on the first visit he was clearly guarding his right shoulder, preventing it from being jolted as he undressed. On examination there was marked tenderness over the biceps groove and acromio-clavicular joint with wasting and loss of muscle power in the trapezius, pectoralis major, levator scapulae and rhomboids. The shoulder was not obviously swollen, but could not be moved beyond a very limited range without considerable pain. Active movements were restricted and painful in all directions, especially internal and external rotation and abduction. The right shoulder abduction was performed by a shrugging of the shoulder with side bending of the head and trunk in order to produce a *trick* movement.

I treated the patient with acupuncture and shoulder exercises using the methods explained earlier in this paper. After the initial session he reported that the shoulder pain had gone, though the stiffness remained. Acupuncture treatment was continued twice weekly for 3 weeks, but although he remained pain free he had only a slight improvement in the degree of stiffness affecting his shoulder mobility. I have suggested to him that, in the long term, gentle swinging exercises may help to reduce the stiffness.

Conclusion

This paper has attempted to clarify the aetiology, clinical features and treatment of frozen shoulder in both Western medical and traditional Chinese terms.

My experience, supported by the analysis of the results of this pilot study, indicates that acupuncture therapy in frozen shoulder offers rapid and effective analgesia and reduction of shoulder stiffness.

On this basis, therefore, I suggest that acupuncture therapy may prove of benefit in medical practice for patients with a clinical diagnosis of idiopathic, arthritic or post-traumatic frozen shoulder. However, investigation of the acupuncture treatment of frozen shoulder by means of an adequately sized, randomised, controlled trial is needed before any valid conclusion can be made about the reliability of its use in medical practice.

Acknowledgment

The author wishes to thank Professor Jack Moreland of the Mackay Institute of Communication and Neuroscience, Keele University, for his advice and valuable comments on statistics.

Emad S Tukmachi MBChB PhD DTM

21 St Edmunds Avenue, Porthill

Newcastle-Under-Lyme, Staffordshire ST5 OAB (UK)

Email: emad@acutuk.freeserve.co.uk

References

1. Bunker TD. Time for a new name for frozen shoulder. *British Medical Journal* 1985; **290**: 1233-4.
2. Duplay S. De la periarthrite scapula-humerales. *L'Abeille Medical* 1896; **53**: 226.
3. Lloyd-Roberts GC, French PR. Periarthritis of a shoulder. *British Medical Journal* 1959; **1**: 1569-71.
4. Neviasser JS. Adhesive capsulitis of the shoulder. *Journal of Bone and Joint Surgery* 1945; **27**: 21 1-22.
5. Bruckner FE. Frozen shoulder (adhesive capsulitis). *Journal of the Royal Society of Medicine* 1982; **75**: 688-9.
6. Hulstyn MT, Weiss APC. Adhesive capsulitis of the shoulder. *Orthopaedic Review* 1993; **22**: 425-33.
7. Reeves B. Natural history of the frozen shoulder syndrome. *Scandinavian Journal of Rheumatology* 1975; **4**: 193-6.
8. Wright V, Haq AMM. Periarthritis of the shoulder. 1. Aetiological considerations with particular reference to personality factor. *Anna/s of Rheumatic Diseases*. 1976; **3**: 213-9.
9. Colvin PC. Radiographic observations in established frozen shoulder. *British Osteopathic Journal* 1982; **14**: 41-6.
10. Colvin PC. The frozen shoulder. *British Osteopathic Journal* 1982; **14**: 87-95.
11. Lee PN, Lee M, Haq AM, Longton EB, Wright V. Periarthritis of the shoulder. *Annals of Rheumatic Diseases* 1974; **33**: 116-9.
12. Leino P, Magni G. Depressive and distress symptoms as predictors of low back pain, neck-shoulder pain, and other musculoskeletal morbidity: a 10 year follow-up of metal industry employees. *Pain* 1993; **53**: 89-94.
13. Fleetcroft JP. *The skeletal system: orthopaedics rheumatology and fractures*. Edinburgh: Churchill Livingstone; 1983. Ch.8: p.83.
14. Binder AI, Bulgen DY, Hazelman BL, Tudor J, Wraight P. Frozen shoulder: an arthrographic and radionuclear scan assessment. *Anna/s of Rheumatic Diseases* 1984; **43**: 359-69.
15. Emig EW. Adhesive capsulitis of the shoulder: MRI Diagnosis. *American Journal of Roentgenology* 1995; **164(4)**: 1457-9.
16. Vecchio PC. Thermography of Frozen Shoulder and rotator Cuff tendonitis. *Clinical Rheumatology* 1992; **11(3)**: 382-4.
17. Cyriax J, Troisier O. Hydrocortisone and soft tissue lesions. *British Medical Journal* 1953; **11**: 966-8.
18. Dacre JE, Beeney N, Scott DL. Injections and physiotherapy for the painful stiff shoulder. *Anna/s of the Rheumatic Diseases* 1989; **48**: 322-5.
19. Harryman DT, Marson FA, Sidles JA. Arthroscopic management of refractory shoulderstiffness. *Journal of Shoulder and Elbow Surgery* 1996; **5**: S24.
20. Rizk TE, Christopher RP, Pinals RS, Higgins AC, Frix R. Adhesive capsulitis (frozen shoulder): a new approach to its management. *Archives of Physical Medicine and Rehabilitation* 1983; **64(1)**: 29-33.

21. Hsu SY, Chan KM. Arthroscopic distention in the management of frozen shoulder. *International Orthopaedics* 1991; **15**: 79-83.
22. Grey RG. The natural history of idiopathic frozen shoulder. *Journal of Bone and Joint Surgery* 1977; **60A**: 564.
23. Parker RD, Froinson AI, Winberg DD, Arsham NZ. Frozen shoulder. Part II: treatment by manipulation under anaesthesia. *Orthopaedics* 1989; **12**: 989-94.
24. Thomas D, Williams RA, Smith DS. The frozen shoulder: a review of manipulative treatment. *Rheumatology and Rehabilitation* 1980; **19**: 173-9.
25. Murnaghan JP. Adhesive capsulitis of the shoulder: Current concepts in treatment. *Orthopaedics* 1988; **11**: 153-158.
26. Collier JAB, Longmore JM, Hodgetts TJ. Orthopaedics and trauma. In: Collier JAB, Longmore JM, Hodgetts TJ, editors. *Oxford Handbook of clinical speciality*. 4th ed. Oxford University Press; 1996. p.656.
27. Ford LT. Tendon rupture after local steroid injection. *Southern Medical Journal* 1997; **72(2)**: 827-30.
28. Sweetnam R. Corticosteroid, arthropathy and tendon rupture. *Journal of Bone and Joint Surgery* 1969; **51 B**: 397-8.
29. Berry L, Fernanders L, Bloom B, Clark RJ, Hamilton EBD. Clinical study comparing acupuncture, physiotherapy, injection and oral anti-inflammatory therapy in shoulder cuff lesion. *Current Medical Research and Opinion* 1980; **7**: 121-6.
30. RheeYG, Eum CM. Arthroscopic release in frozen shoulder. *Journal of Shoulder and Elbow Surgery* 1996; **5**: S26.
31. Segmuller E, Taylor DE, Hogan CS, Saies AD, Hayes MO. (1995) Arthroscopic treatment of adhesive capsulitis. *Journal of Shoulder and Elbow Surgery* 1995; **4**: 403-8.
32. Pollock RG. The use of Arthroscopy in the treatment of resistant frozen shoulder. *Clinical Orthopaedics* 1994; **303**: 30-6.
33. Janda DH, Hawkins RJ. (1993) Shoulder manipulation in patients with adhesive capsulitis and diabetes mellitus: A technical note. *Journal of Shoulder and Elbow Surgery* 1993; **2**: 36-8.
34. Uitvlugt G. Arthroscopic observations before and after manipulation of frozen shoulder. *Arthroscopy* 1993; **9(2)**: 181-5.
35. Teale TP. On the relief of pain and muscular disability by acupuncture. *Lancet* 1871. i: 567-8.
36. Skrabanek P. Acupuncture and the age of unreason. *Lancet* 1984. i: 1169-71.
37. Ross J. *Acupuncture point combinations: the key to clinical success*. Edinburgh: Churchill Livingstone; 1995. p.369-70.
38. Miyawaki K. Effective cases of meridian therapy (6): Frozen shoulder. *Journal of Japanese Acupuncture and Moxibustion* 1984; **43(II)**: 34-9.
39. Baldry PE. *Acupuncture, trigger points and musculoskeletal pain*. Edinburgh: Churchill Livingstone; 1989. p.122-5.
40. Travell JG, Simons DC. *Myofascial pain and dysfunction: the trigger point manual*. Baltimore: Williams & Wilkins; 1983.
41. Shanghai Institute of Acupuncture Research, Sheng Mu, editor. *A handbook of acupuncture*. Hong Kong; 1972.
42. Pothmann R, Stux G, Weigel A. Frozen shoulder: differential acupuncture therapy with point ST 38. *American Journal of Acupuncture* 1980; **8(1)**: 65-9.
43. Nguyen J. Relation between Tiaokou (ST 38) and mobility of the shoulder. *Rev. Fr. Med. Tradit. Chin.* 1984; **103**: 497-9.
44. Wiseman N, trans. Diseases and its causes. In: *Fundamentals of Chinese medicine*. Massachusetts: Paradigm Publications; 1995. p.77-87.
45. Low R. *The acupuncture treatment of musculo-skeletal conditions: a practical handbook for the practitioner*. Wellingborough: Thorsons; 1987. p.37.
46. Mann F. *Reinventing acupuncture: a new concept of ancient medicine*. Oxford: Butterworth-Heinemann; 1992. p.168-70.
47. Academy of Traditional Chinese Medicine. *Essentials of Chinese Acupuncture*. Beijing: Foreign Languages Press; 1980. p.400.
48. Tiquia R. *Traditional Chinese medicine: a guide to its practice*. Egerton L, editor. Australia: Choice Book; 1996. p.148-56.
49. Shaffer B, Tibone JE, Kerlan RK. (1992) Frozen shoulder: A long-term follow-up. *Journal of Bone and Joint Surgery* 1992; **74(5)**: 738-46.
50. Camp V. Acupuncture for shoulder pain. *Acupuncture in Medicine* 1986; **3**: 28,32.
51. Camp V. Acupuncture for rheumatological problems. In: Filshie J, White A, editors. *Medical acupuncture: a western scientific approach*. Edinburgh: Churchill Livingstone; 1998. p.341-60.
52. Moore ME, Berk SN. Acupuncture for chronic shoulder pain: an experimental study with attention to the role of placebo and hypnotic susceptibility. *Annals of Internal Medicine* 1976; **84**: 381-4.
53. Veith I, trans. *Huang Ti Nei Ching Su Wen (The Yellow Emperor's Classic of Internal Medicine)*. Berkeley: University of California Press; 1972. Ch.5.
54. Tukmachi ESA. Acupuncture and pain: general consideration. *Inter Medica* 1991; **1**: 11-9.
55. Ulett GA. *Principle and practice of physiologic acupuncture*. St. Louis, Missouri: Warren H Green; 1982. p.220.
56. Tukmachi ESA. A place for acupuncture in treatment of osteoarthritis: two case reports. *British Journal of Acupuncture* 1991 ;**14**: 2-3.
57. Tukmachi ESA. Acupuncture therapy in patients unresponsive to orthodox treatment. *Inter Medica* 1991; **1**: 19-23.
58. Tukmachi ESA. Lumbago: theoretical studies and treatment by traditional Chinese acupuncture. *British Journal of Acupuncture* 1992; **15(1)**: 12-8.
59. Ekelund AL, Rydell H. Combination treatment for adhesive capsulitis of the shoulder. *Clinical Orthopaedics* 1992; **282**: 105-9.



**THE ASSOCIATION OF
BRITISH VETERINARY ACUPUNCTURE**
invites new members

Enquiries please to:
The President, Mr John Nicol or
The Secretary, Mrs Jill Hewson
East Park Cottage, Handcross Sussex RH17 6BD



Frozen shoulder: a comparison of Western and traditional Chinese approaches and a clinical study of its acupuncture treatment

Emad S Tukmachi

Acupunct Med 1999 17: 9-21
doi: 10.1136/aim.17.1.9

Updated information and services can be found at:
<http://aim.bmj.com/content/17/1/9>

Email alerting service

These include:

Receive free email alerts when new articles cite this article. Sign up in the box at the top right corner of the online article.

Notes

To request permissions go to:
<http://group.bmj.com/group/rights-licensing/permissions>

To order reprints go to:
<http://journals.bmj.com/cgi/reprintform>

To subscribe to BMJ go to:
<http://group.bmj.com/subscribe/>